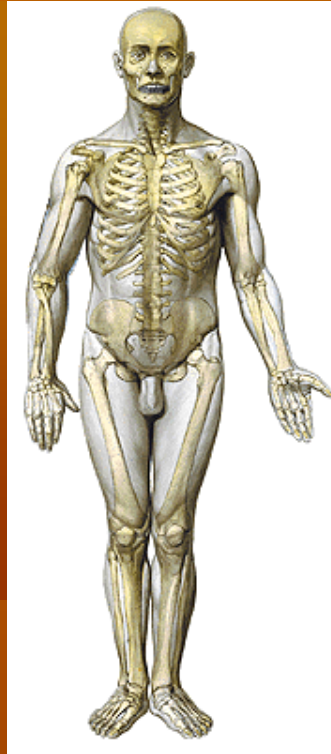

ANATOMI EXTREMITAS SUPERIOR

TIM ANATOMI

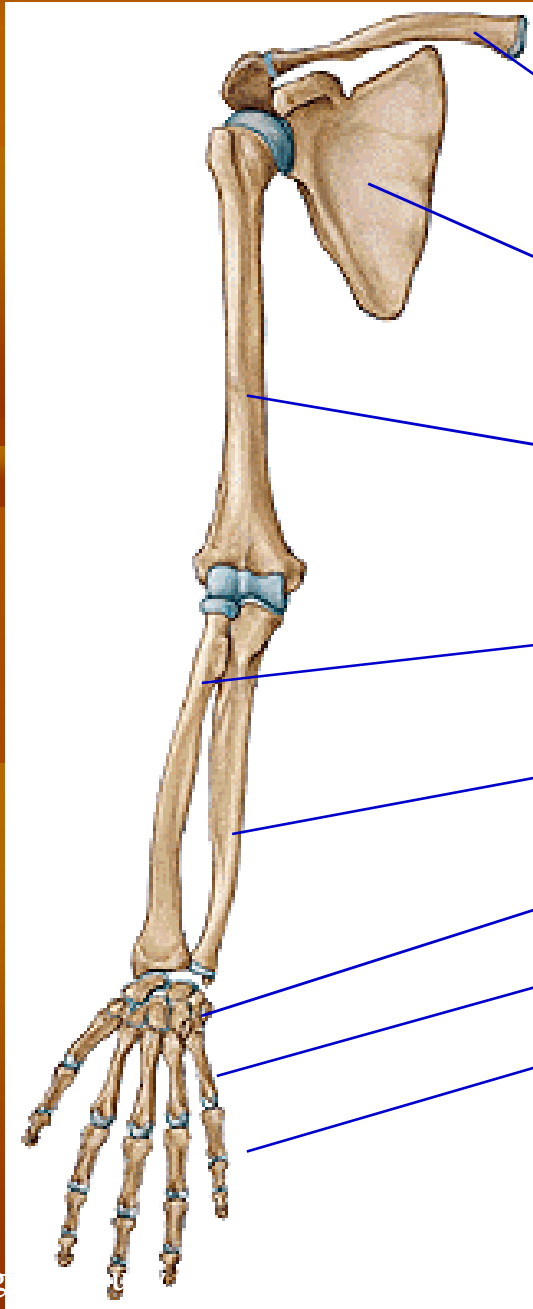
FIK Universitas Negeri Yogyakarta

danangvega@uny.ac.id



OSTEOLOGI

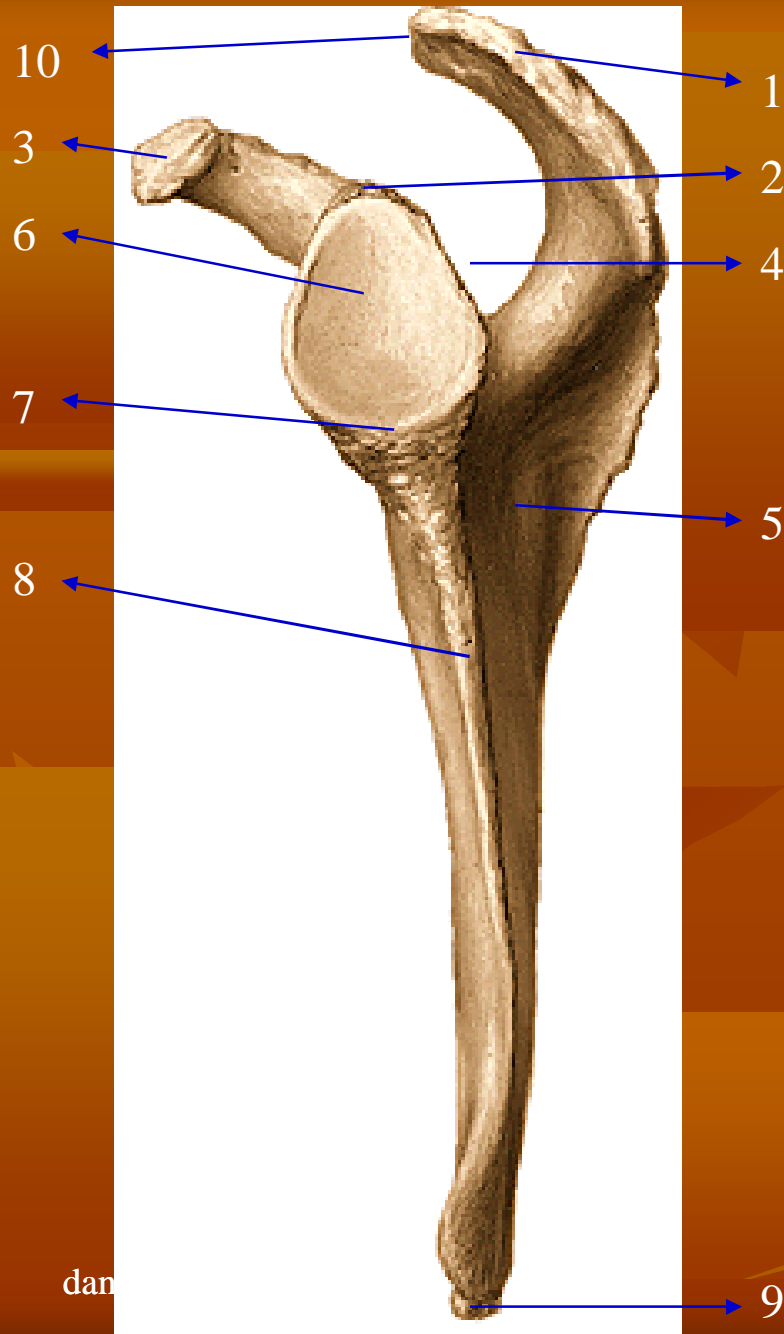
danangvega@uny.ac.id



TULANG-TULANG
EXTREMITAS SUPERIOR
TERDIRI DARI:

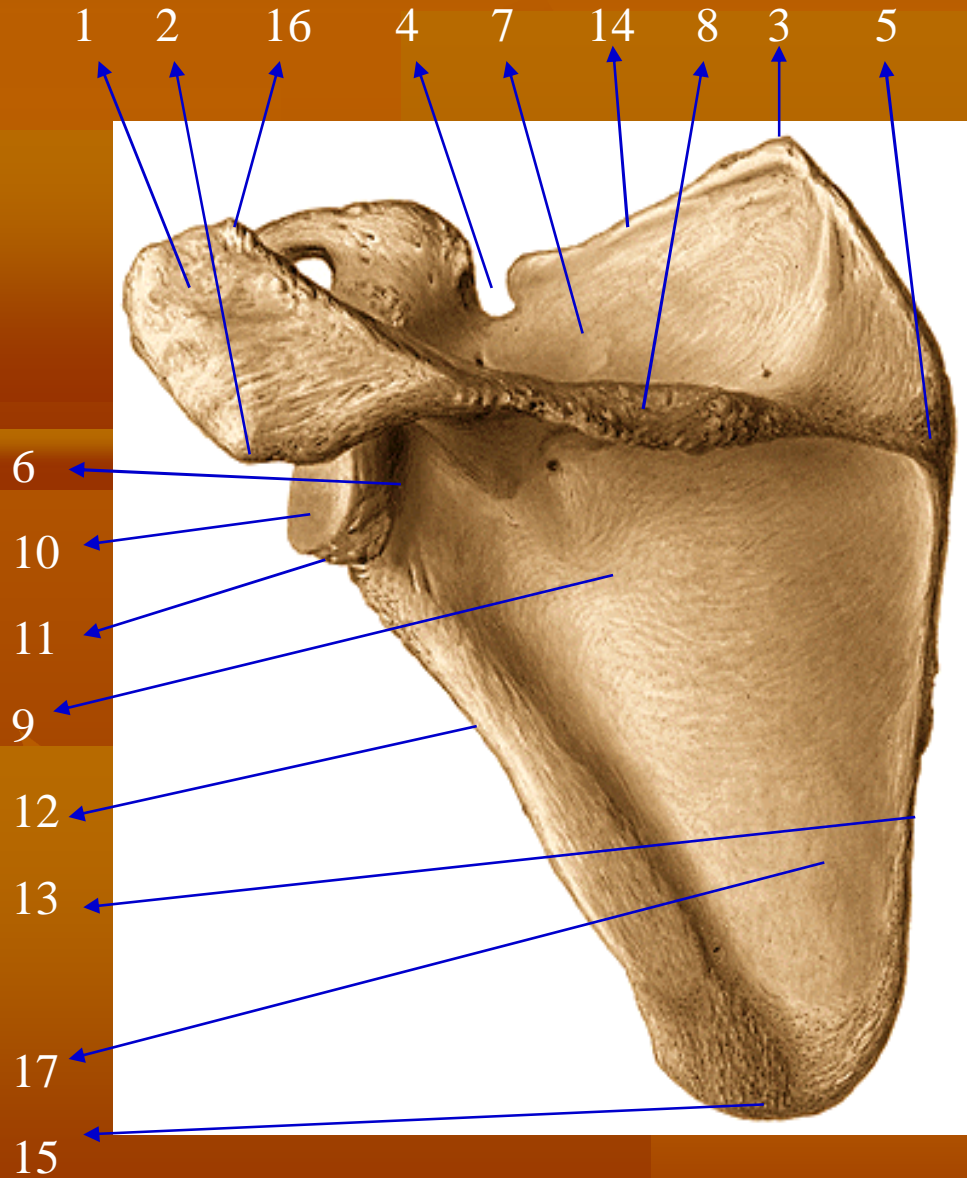
1. Os clavícula
2. Os scapula
3. Os humerus
4. Os radius
5. Os ulna
6. Ossa carpalia
7. Ossa metacarpalia
8. Ossa phalanges

OS SCAPULA



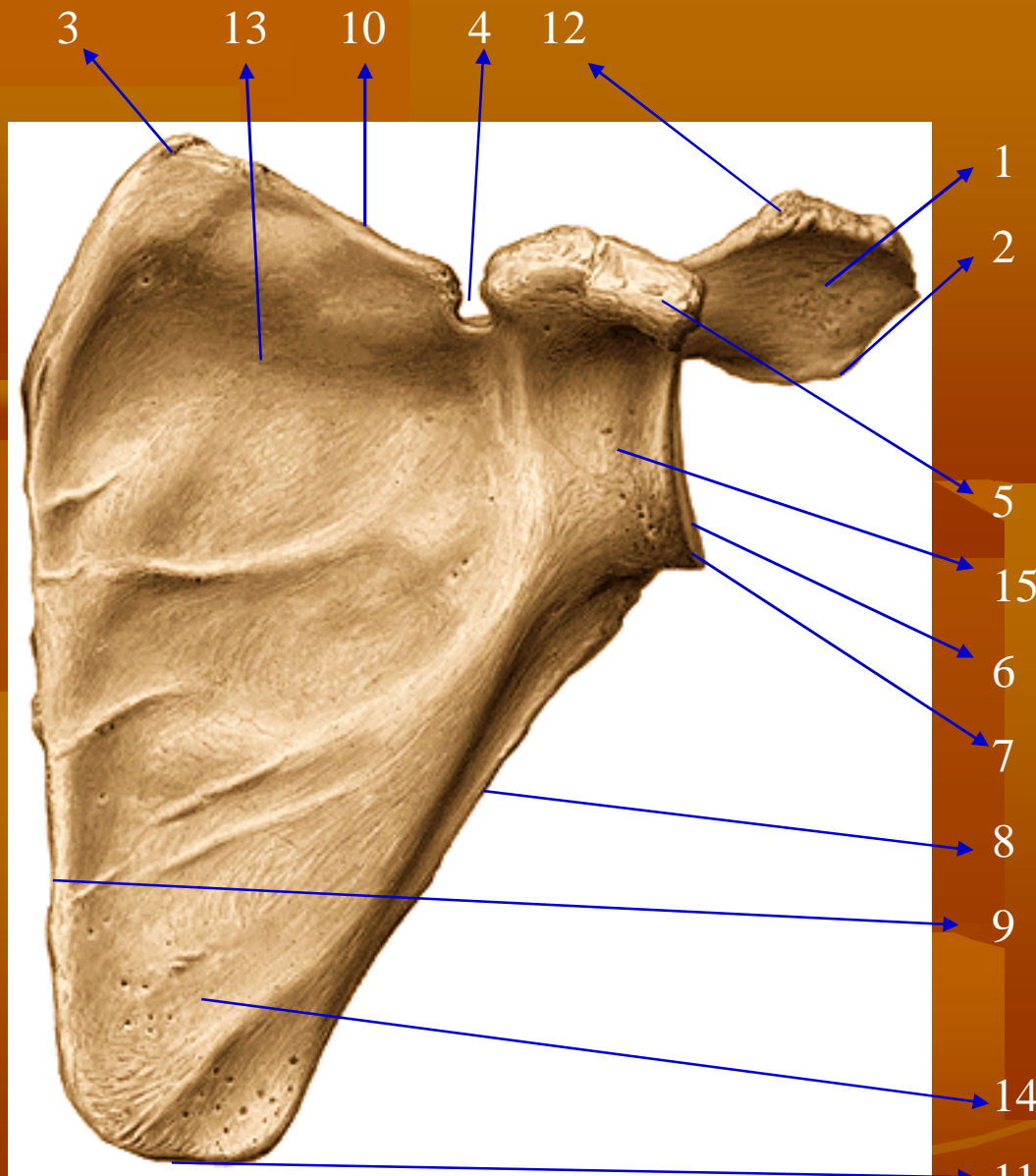
1. Acromion
2. Tuberculum supraglenoidale
3. Processus coracoideus
4. Fossa supraspinata
5. Fossa infraspinata
6. Cavitas glenoidalis
7. Tuberculum infraglenoidale
8. Margo lateralis/axillaris
9. Angulus inferior
10. Facies articularis acromii

OS SCAPULA



1. Acromion
2. Angulus acromialis
3. Angulus superior
4. Incisura scapulae
5. Trigonum spina scapulae
6. Collum scapulae
7. Fossa supraspinata
8. Spina scapulae
9. Fossa infraspinata
10. Cavitas glenoidalis
11. Tuberculum infraglenoidale
12. Margo lateralis/axillaris
13. Margo medialis/vertebralis
14. Margo superior
15. Angulus inferior
16. Facies articularis acromii
17. Linea m. scapulae

OS SCAPULA

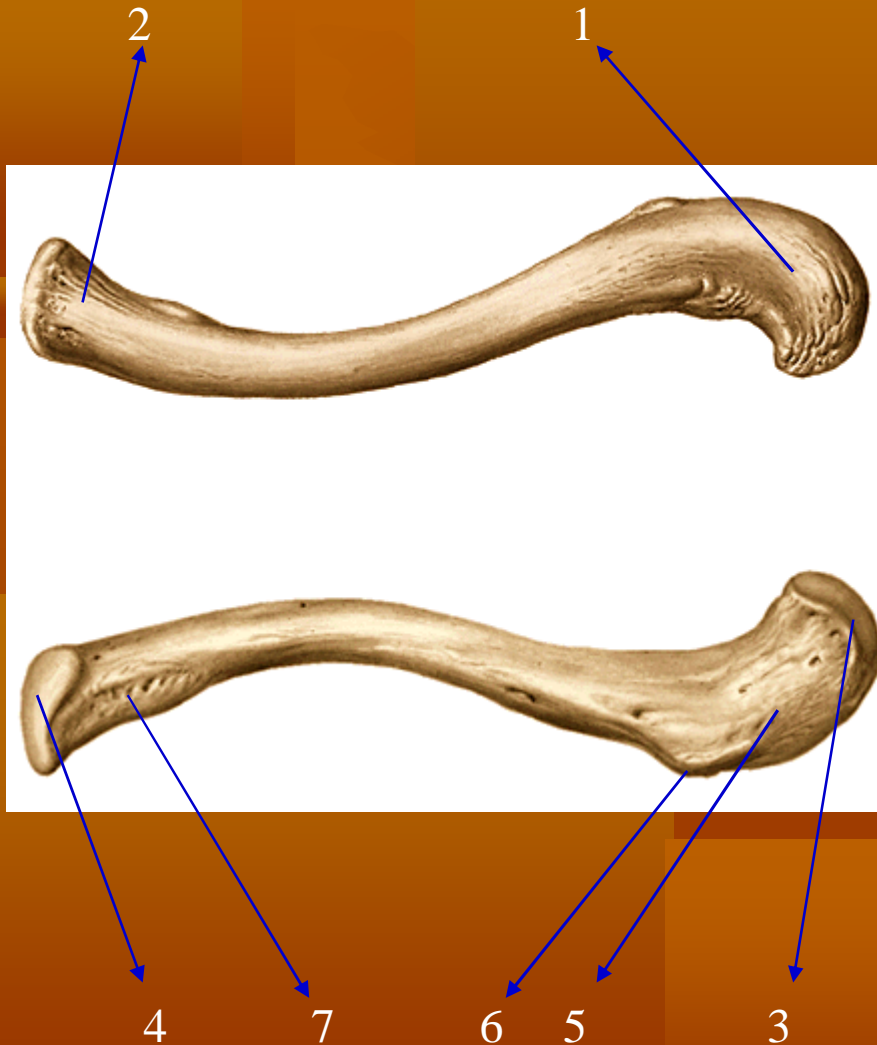


1. Acromion
2. Angulus acromialis
3. Angulus superior
4. Incisura scapulae
5. Processus coracoideus
6. Cavitas glenoidalis
7. Tuberculum infraglenoidale
8. Margo lateralis/axillaris
9. Margo medialis/vertebralis
10. Margo superior
11. Angulus inferior
12. Facies articularis acromii
13. Fossa subscapularis
14. Facies costalis
15. Collum scapulae

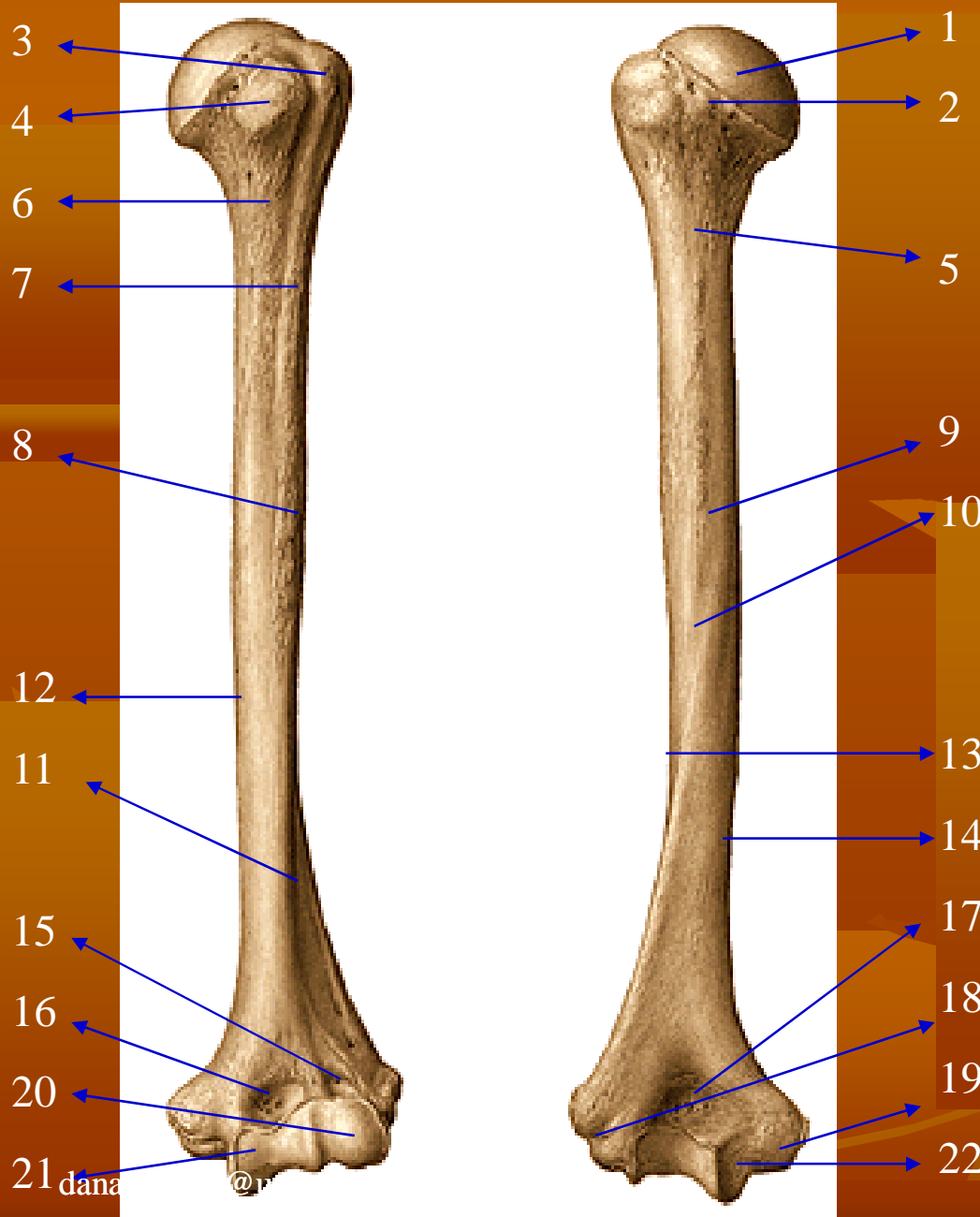
OS CLAVICULA

(kiri)

1. Extremitas acromialis
2. Extremitas sternalis
3. Facies articularis acromialis
4. Facies articularis sternalis
5. Linea trapezoidea
6. Tuberculum conoideum
7. Impressio ligamenti costoclavicularis

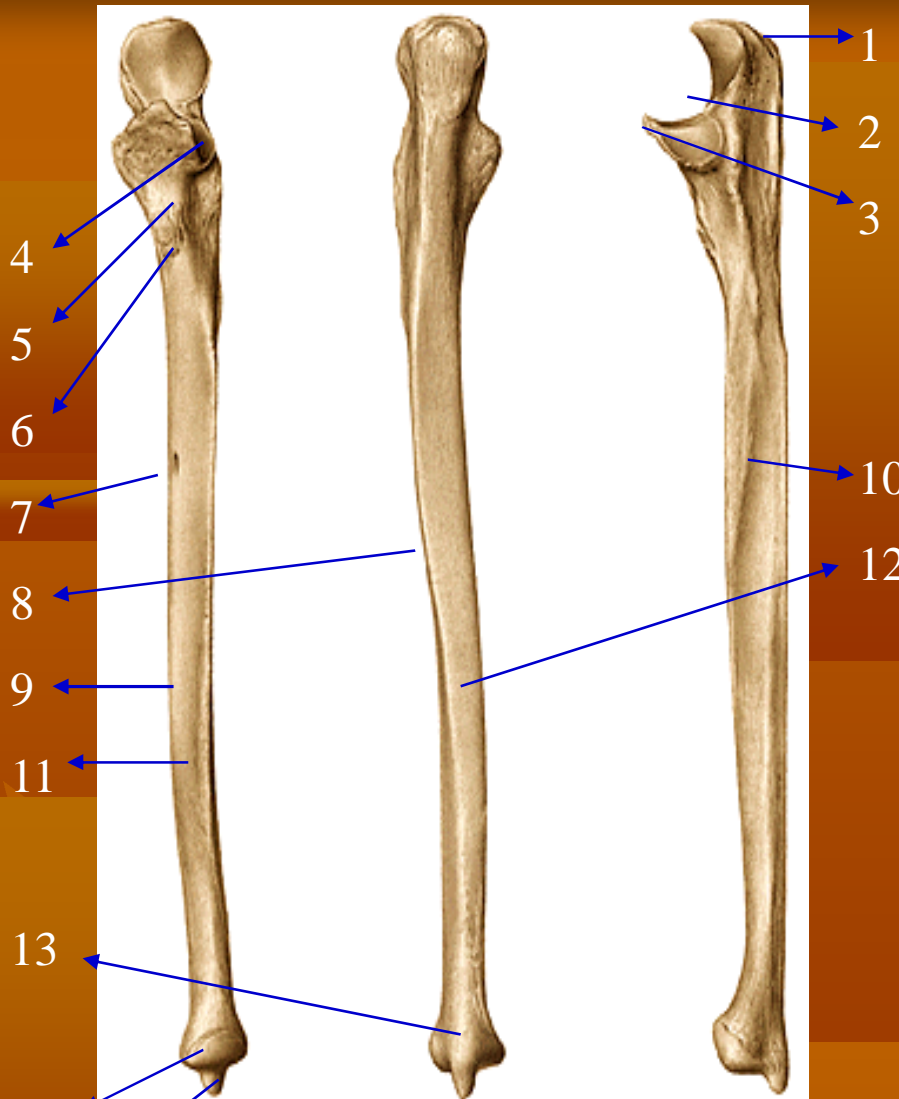


OS HUMERUS

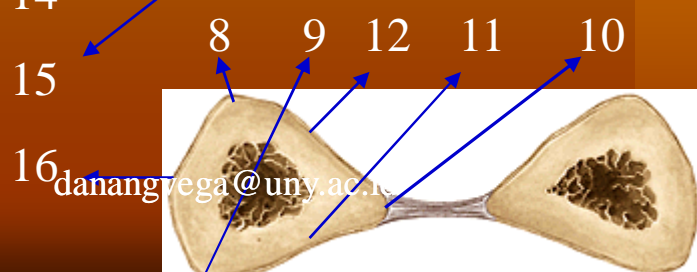


1. Caput humeri
2. Collum anatomicum
3. Tuberculum majus
4. Tuberculum minus
5. Collum chirurgicum
6. Crista tuberculi minoris
7. Crista tuberculi majoris
8. Tuberositas deltoidea
9. Sulcus nervi radialis
10. Facies posterior
11. Facies anterior lateralis
12. Facies anterior medialis
13. Margo lateralis
14. Margo medialis
15. Fossa radialis
16. Fossa coronoidea
17. Fossa olecrani
18. Epicondylus lateralis
19. Epicondylus medialis
20. Capitulum humeri
21. Trochlea humeri
22. Sulcus nervi ulnaris

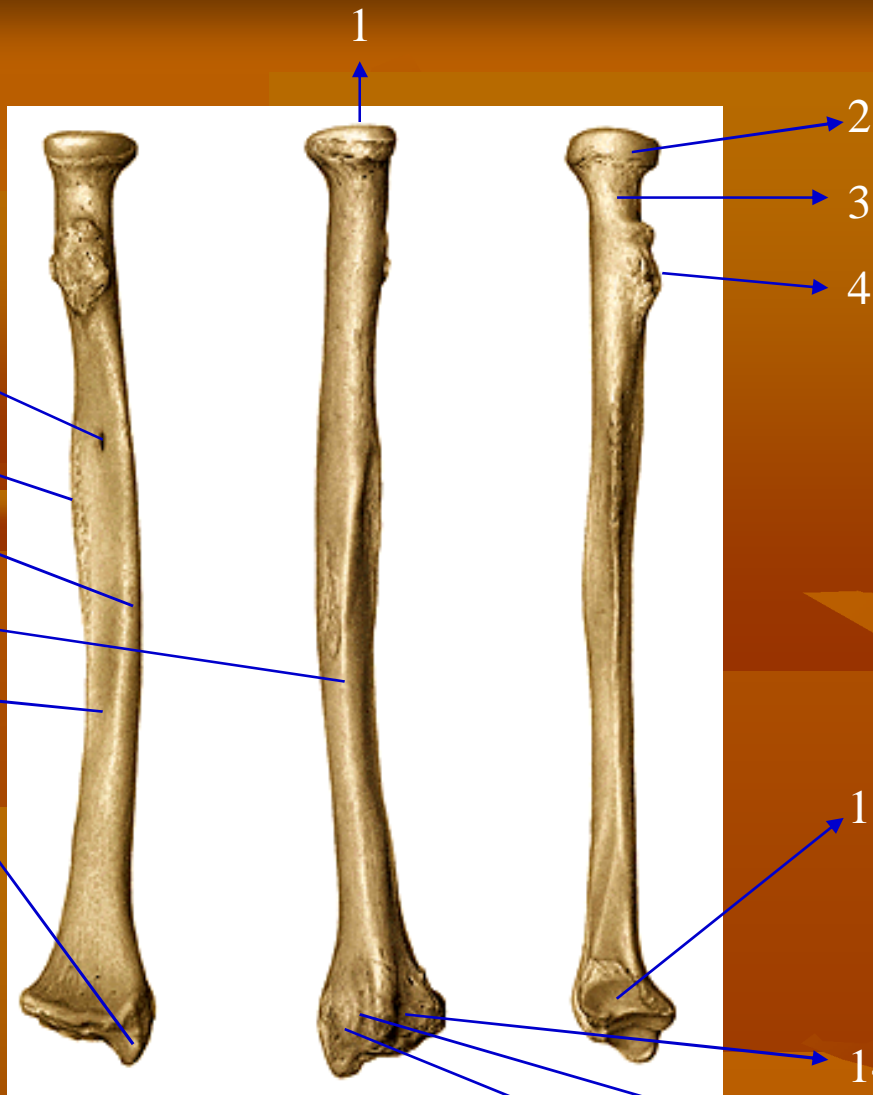
OS ULNAE



1. Olecranon
2. Incisura trochlearis
3. Processus coronoideus
4. Incisura radialis
5. Crista supinatoris
6. Tuberositas ulnae
7. Foramen nutricium
8. Margo posterior
9. Margo anterior
10. Margo interossea
11. Facies anterior
12. Facies posterior
13. Kaput ulnae
14. Circumverentia articularis ulnae
15. Processus stiloideus
16. Facies medialis



OS RADIUS



5
6
7
8
9
10

2
3
4
11
12
13
14
15
16

1. Fovea articularis capituli radii
2. Circumverentia articularis radii
3. Collum radii
4. Tuberositas radii
5. Foramen nutricium
6. Margo interossea
7. Margo anterior
8. Facies posterior
9. Facies anterior
10. Processus stiloideus
11. Incisura ulnaris
12. Sulcus mm. extensorum carpi radialium
13. Sulcus m. extensoris policis longi
14. Sulcus mm. extensoris digitorum et extensoris indicis
15. Margo posterior
16. Facies lateralis

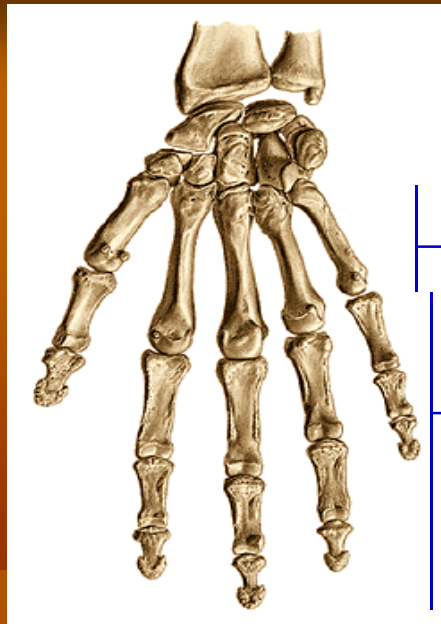

danangvega@uny.ac.id

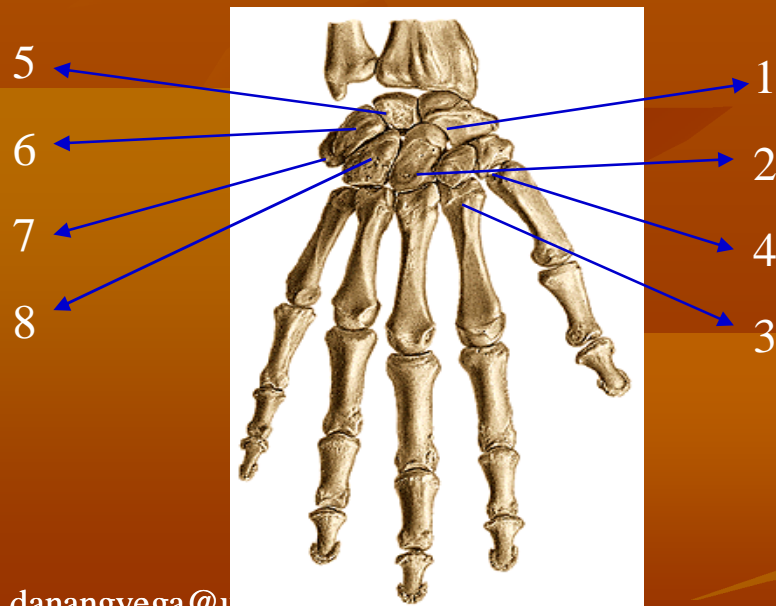
OSSA CARPALIA

(kanan)

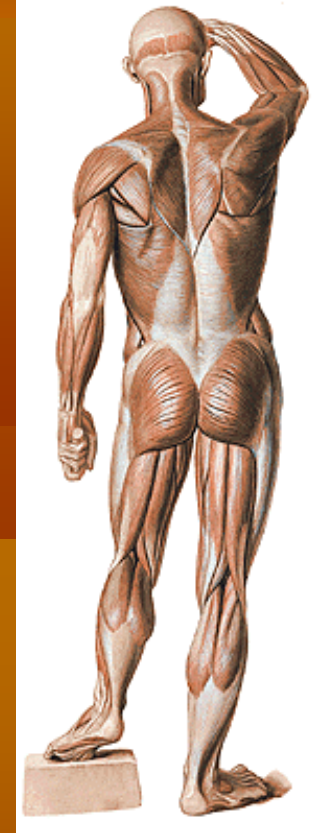
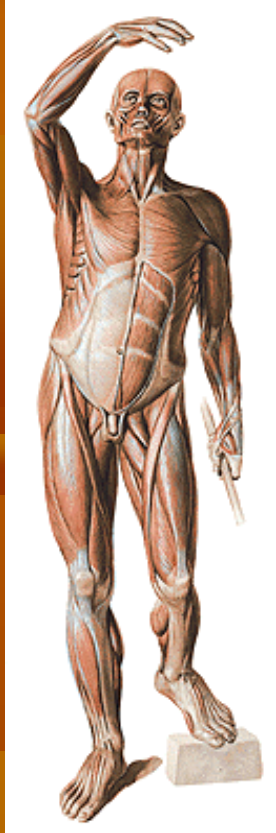1. Os schapoideum
2. Os capitatum
3. Os trapezoideum
4. Os trapezium
5. Os lunatum
6. Os triguetrum
7. Os pisiforme
8. Os hamatum
9. OSSA METACARPALIA
10. OSSA DIGITORUM:
 - a. phalanx proximalis
 - b. phalanx media
 - c. phalanx distalis



ventral



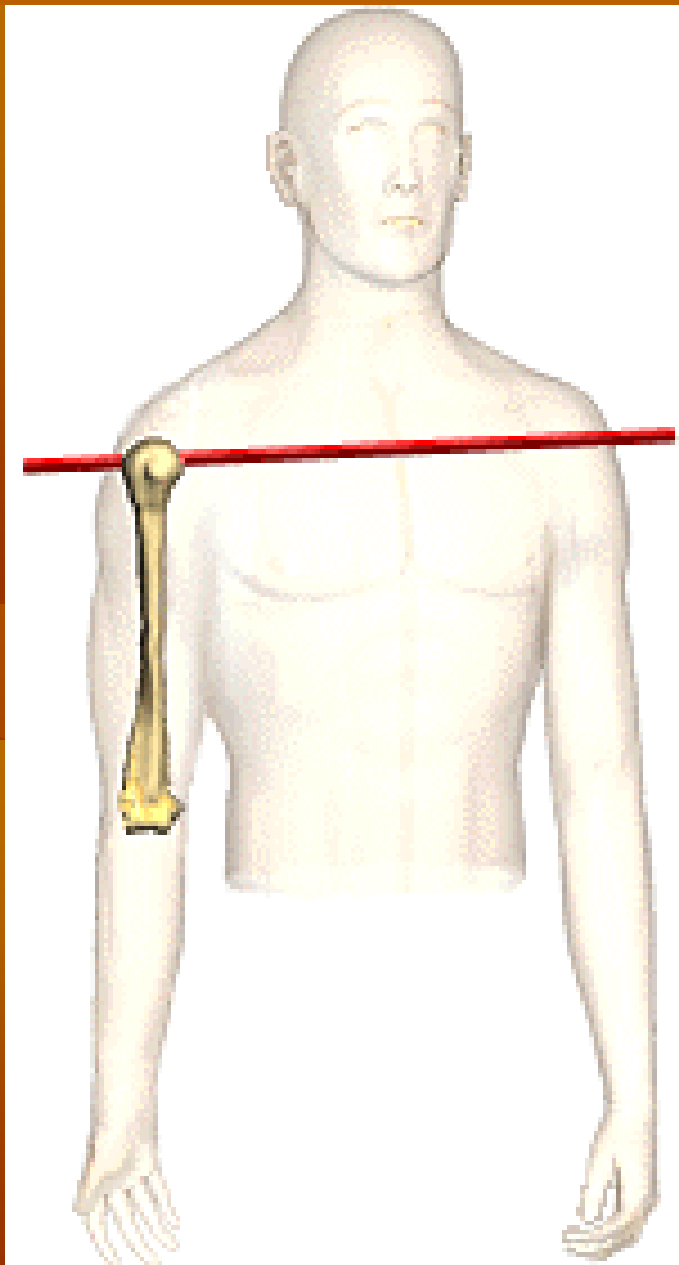
dorsal

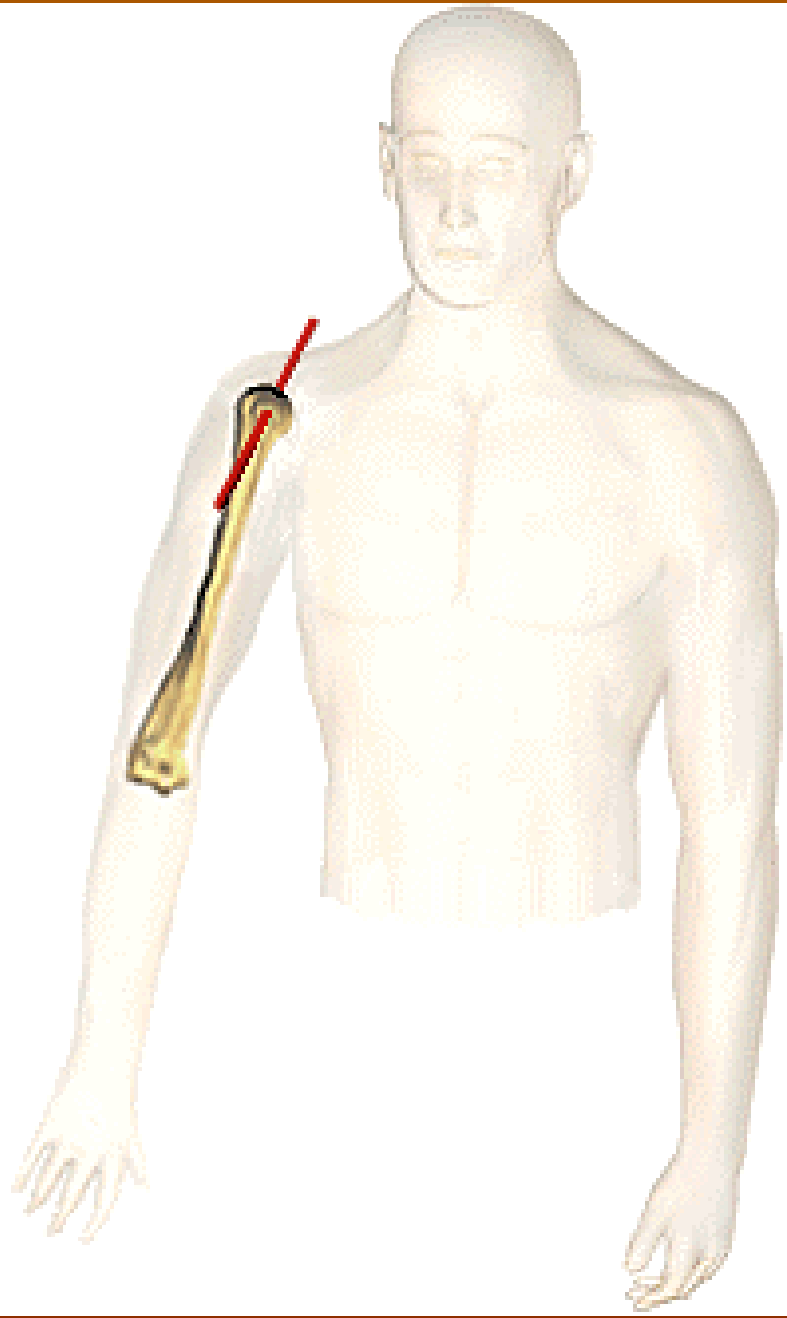


SISTEM ALAT GERAK ANGGOTA BADAN ATAS

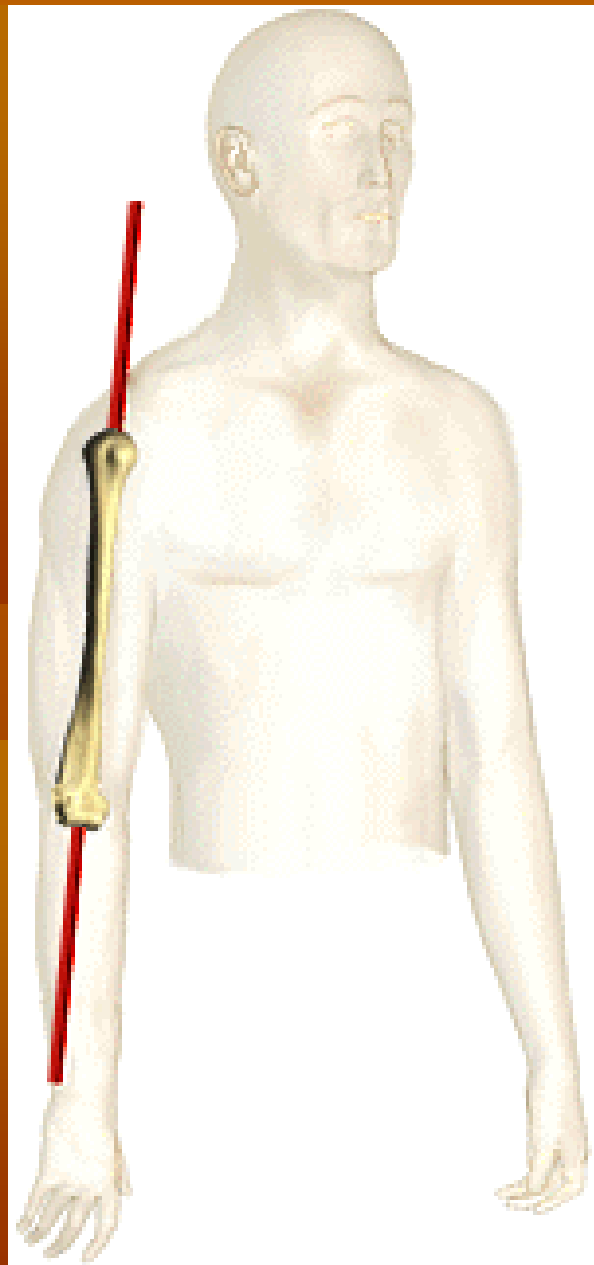
Prinsip dasar terjadinya suatu gerakan:

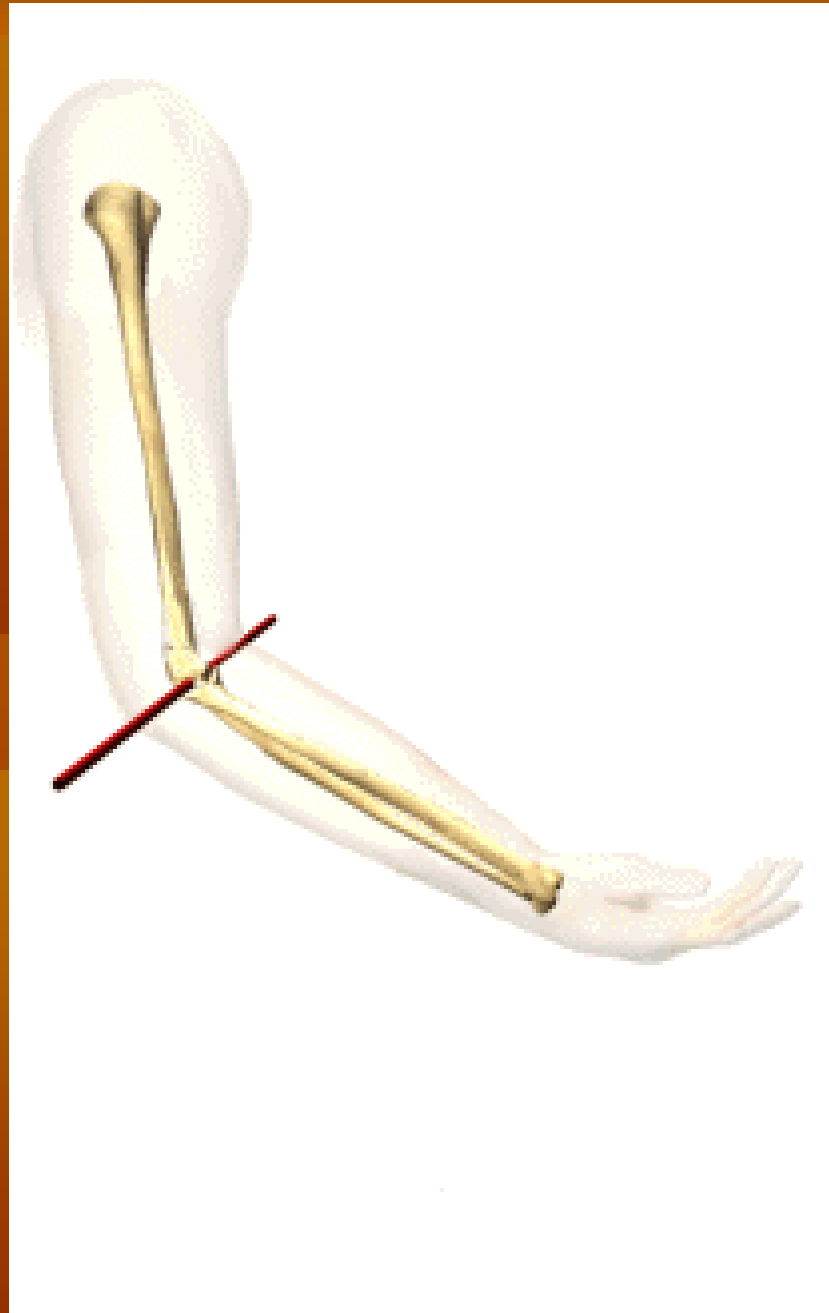1. Otot harus berkontraksi dan menyilangi sendi (kecuali yang melekat pada kulit atau organ tubuh)
2. Gerakan saat kontraksi otot: *insersio* → *origo*
3. Sendi: bisa satu aksis/lebih
4. Posisi persilangan otot thd aksis → arah gerakan.
5. Otot dapat menyilangi lebih dari satu aksis sesuai dengan jumlah aksis pada sendi yang disilanginya
6. Otot dapat menyilangi satu sendi (monoartikuler), dan menyilangi lebih dari satu sendi (polyartikuler)
7. Bidang gerakan otot selalu tegak lurus dengan aksisnya.

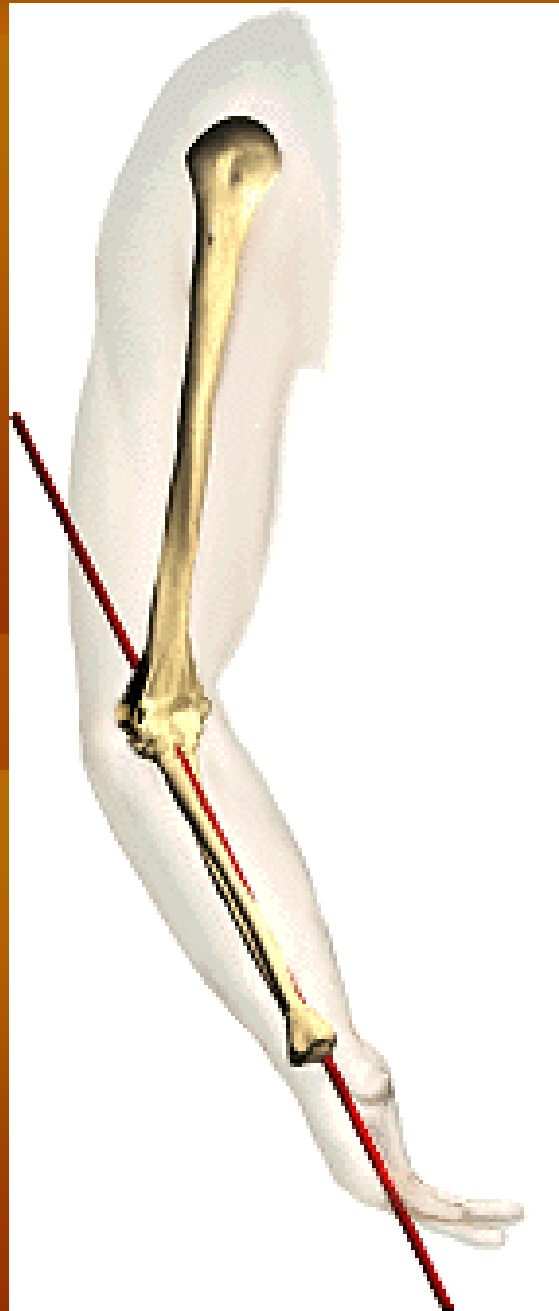


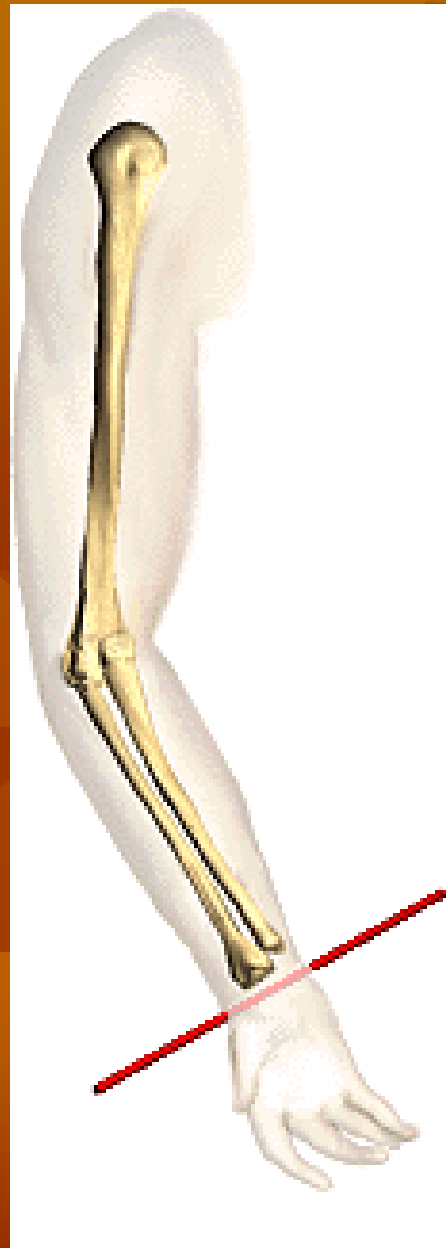

danangvega@

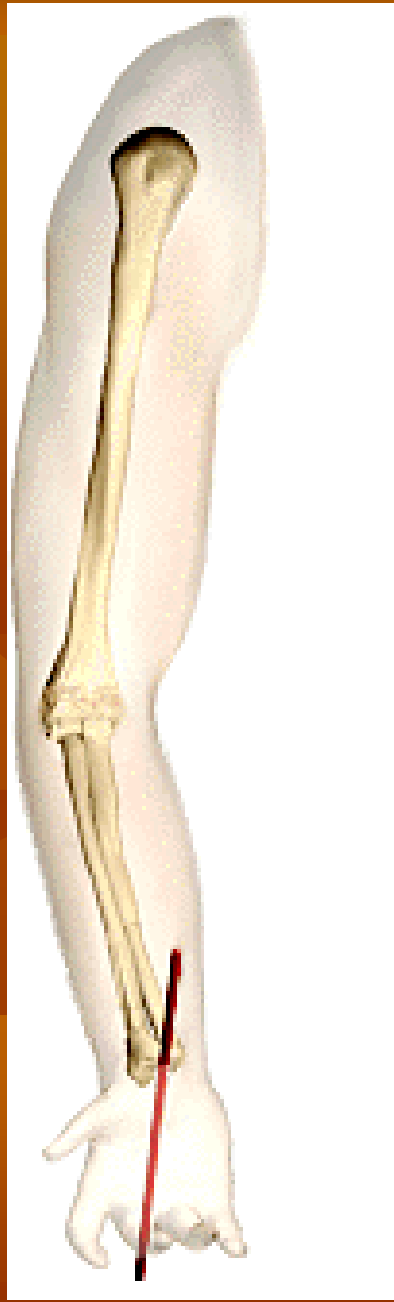







danangvega@uny.ac.id



Ekstremitas superior

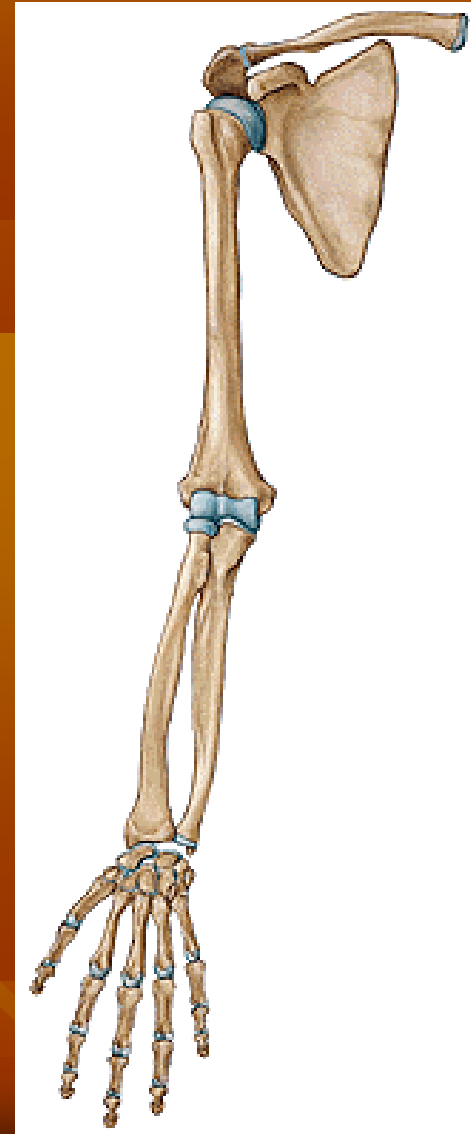
Dibedakan menjadi 2 bagian:

1. Tulang-tulang gelang bahu

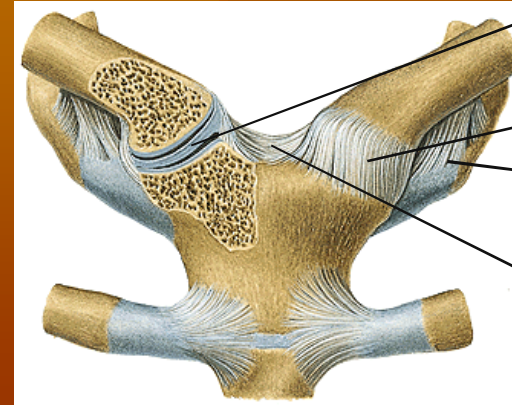
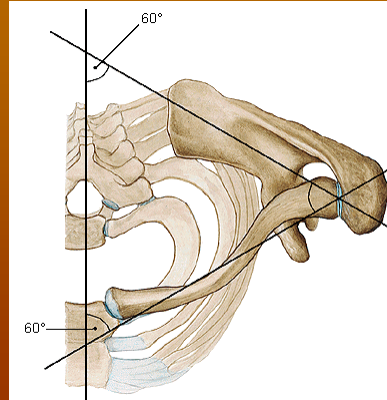
- a. os. Claviculae
- b. os. scapulae

2. Tulang anggota badan bebas

- a. os. Humerus
- b. os. Radius
- c. os. Ulnae
- d. ossa manus
 - d.1. ossa carpalia (8 tulang)
 - d.2. ossa metacarpalia (5 tulang)
 - d.3. ossa digitorum manus



SENDI-SENDI ANGGOTA BDAN ATAS



Discus articularis

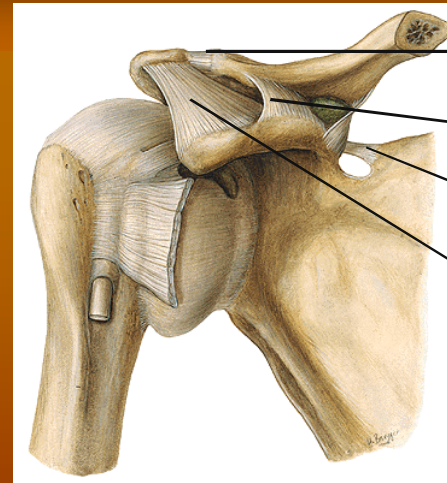
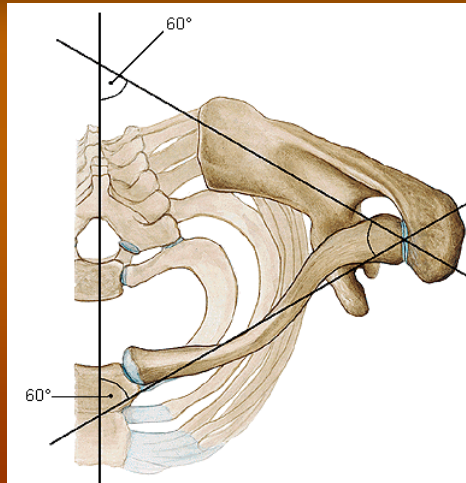
Lig. Sternoclav.

Lig. Costoclavic.

Lig. Interclavic.

1. ART. STERNO-CLAVICULARIS:

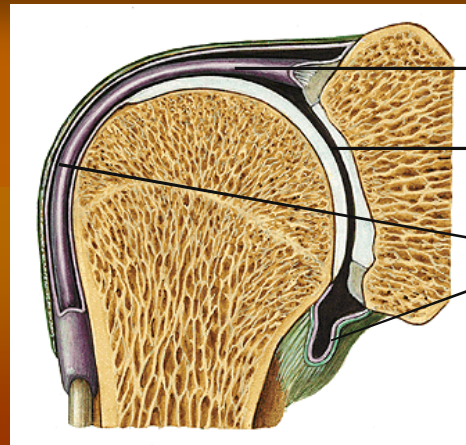
- Berdasar Σ tulang \rightarrow art. Simpleks: sternum-clavicula
- Berdasar Σ aksis \rightarrow art. triaksial
- Berdasar bentuk permukaan \rightarrow art. Sellaris
- Scr fungsional \rightarrow sendi peluru (sirkumduksi/putaran)



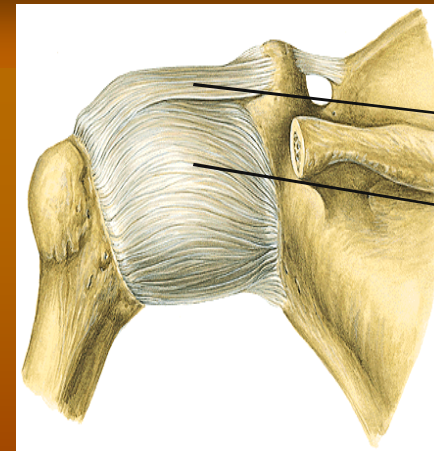
- Lig. Acromioclavic.
- Lig. Coracoclavic
- Lig. Transversum scap.
- Lig. Coracoacromiale

2. ART. ACROMIOCLAVICULARIS:

- Scr. Fisiologis → sendi peluru (3 aksis)
- Berdasar bentuk permukaan sendi → art. Globoidea/spheroidea
- Berdasar Σ aksis → art. triaksial
- Berdasar Σ tulang → art. Simpleks: acromion-clavicula



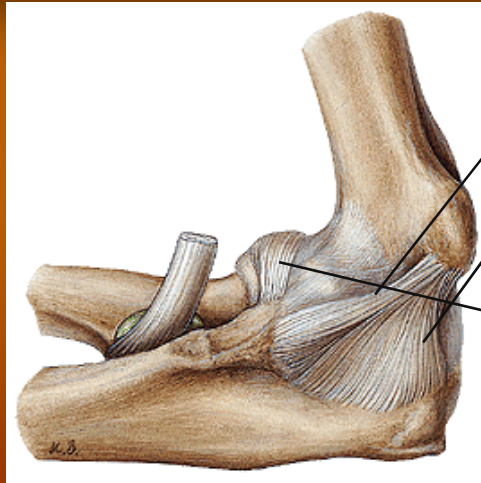
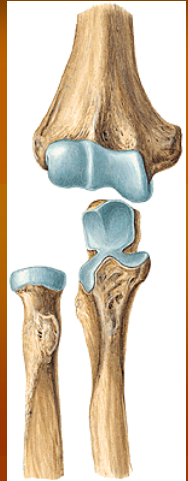Tendo m. biceps
 Cartilago articulare
 Capsul sendi



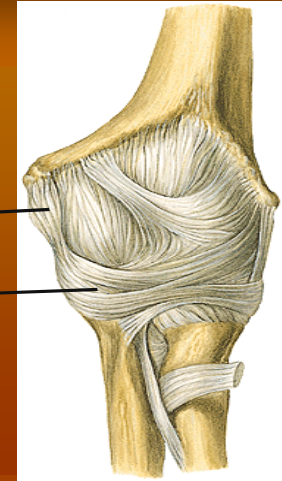
1
 Lig. Coracohumerale
 Lig. Glenohumerale:
 (sup., med., inf.)

3. ART. HUMERI:

- Berdasar bentuk permukaan → art. Globoidea/spheroidea
- Berdasar Σ aksis → triaksial
- Berdasar Σ tulang yang bersendi → simpleks
- Keistimewaan: ada tendo yang melewati ruang sendi
- Selain ligamentum, juga diperkuat oleh otot: m supraspinatus, m infraspinatus, m teres minor, m subscapularis, m deltoideus.
- Luxatio ???



Lig. Collaterale ulnae anterior
Lig. Collaterale ulnae posterior
Lig. Collaterale radiale
Lig. Anulare radii



4. ART. CUBITI (SENDI SIKU):

- Berdasar Σ tlg yang bersendi \rightarrow art. Composita
- Ada 3 bagian : (1) art. Humeroulnaris; (2) art. Humeroradialis; (3) art. Radioulnaris proksimalis

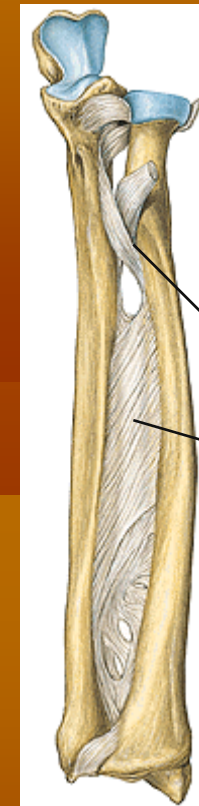
HUBUNGAN ANTARA RADIUS-ULNA:

1. DIASTHROSIS:

Art. Radioulnaris proximalis & distalis

2. SYNARTHROSIS:

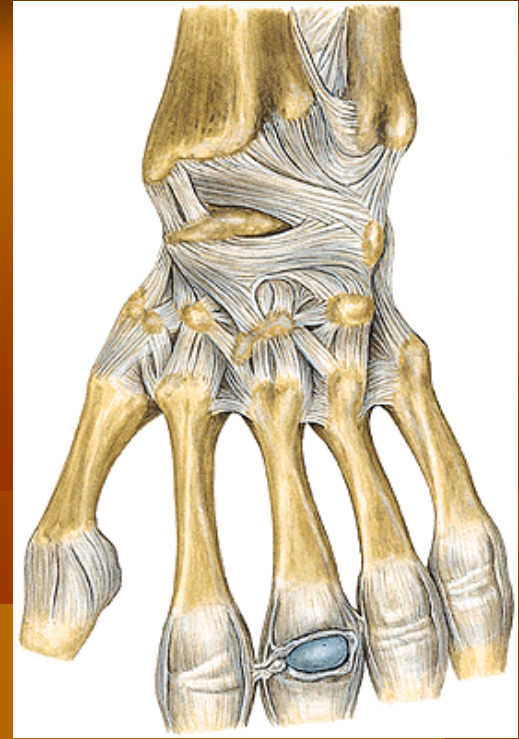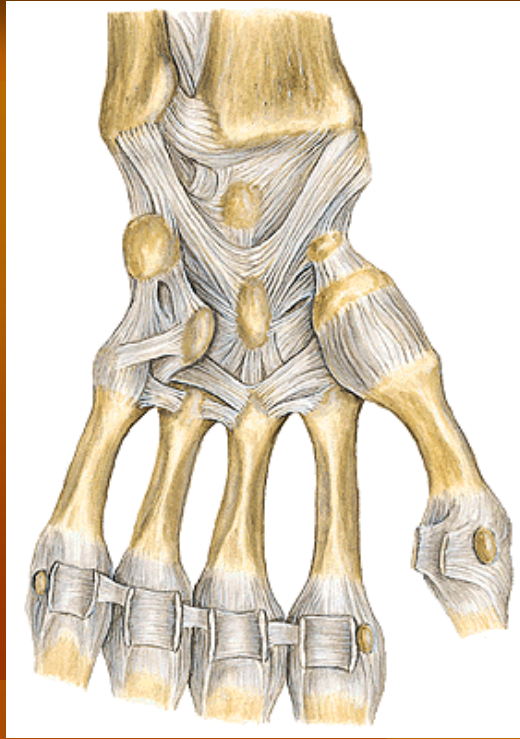
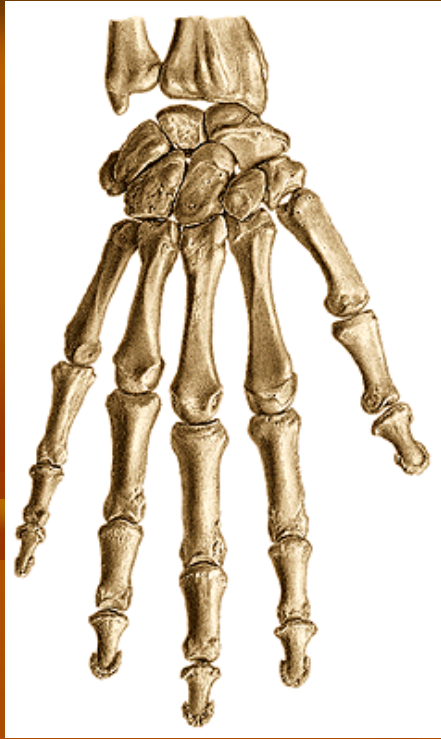- Berupa syndesmosis radioulnaris (membrana interossea antebrachii)
- Arah serabut miring dari radial atas ke ulna bawah → Fx: melanjutkan gaya dari radius
- Serabut yang lain berlawanan arah: “chorda obliqua”



Chorda obliqua

Membr. Interossea





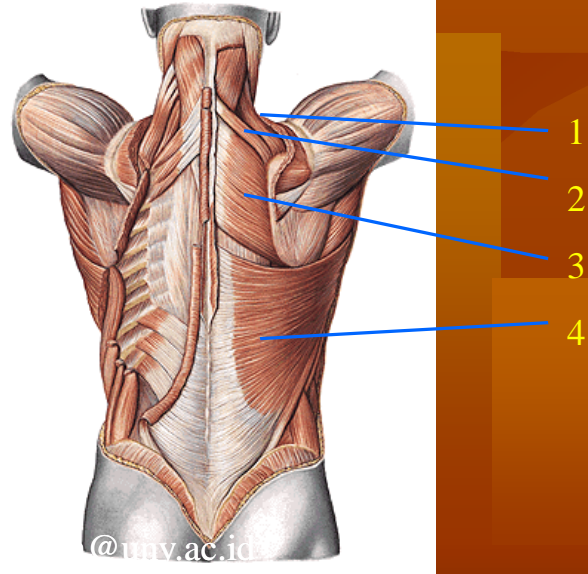
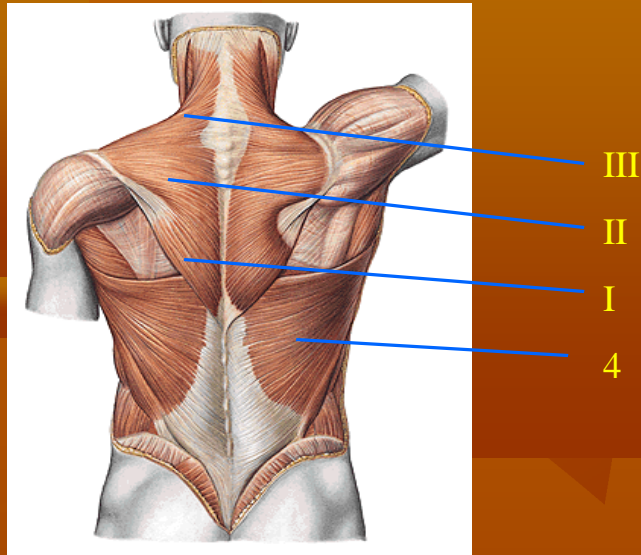
5. ART. RADIOCARPEA:

- Sendi antara lengan bawah – pergelangan tangan
- Merupakan art. Elipsoidea (2 aksis): transversal & sagital

6. ART. METACARPO-PHALNGEAE

7. ART. INTERPHALANGEAE

OTOT BAHU



1. M levator scapulae

o: tub. Post VC1-4
i: angulus med scap
f: mengangkat/men
atik scap ke medial

2. M rhomboideus minor

o: proc spin VC 6-7
i: margo vert scap+ basis
spin scap
f: menarik scap ke med

3. M rhomboideus major

o: proc spin VT 1-4
i: margo vert scap
f: menarik scap ke med

4. M latissimus dorsi

o: proc spin VT 7-12
VL1-5, cr iliaca
i: cr tub min humeri
f: dorsofl, add, endorot
lengan

5. M trapezius

I. pars ascendens

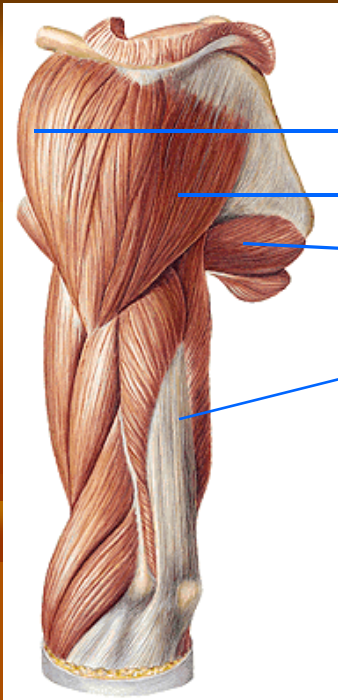
o: proc spin VT 3-12
i: bag med spin scap
f: menarik scap kebwh

II. Pars transversa


o: proc spin VC 7 VT1-3
i: bag lat spin scap
f: menarik scap ke med

III. Pars descendens

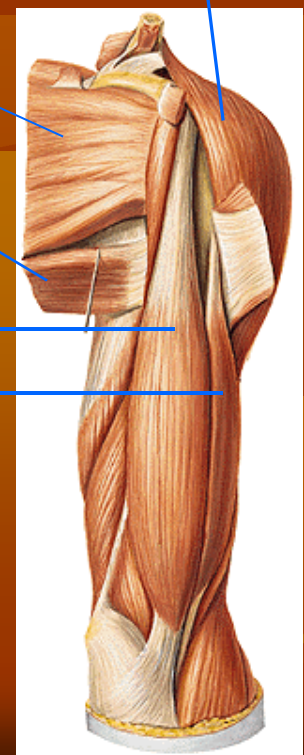
o: protub occ ex 1 n sup,
lig nuchae
i: 1/3 lat clavicula
f: menarik scap ke atas



1B
1C
6
7



5
6
2
3
7A
7B
7C



1A

danangve @uny.ag.id

1. M deltoideus

A. Pars clavicularis

o: bag lateral clavicula
f: antefleksi lengan atas

B. Pars acromialis

o: acromion
f: abduksi lengan atas

C. Pars spinalis

o: spina scapulae
f: dorsofleksi lengan atas
i: tuberositas deltoidea

2. M biceps brachii cap breve

o: procesus coracoideus
f: antefl & add lengan atas

3. M biceps brachii cap long.

o: tub supra glenoidales
f: antefl & abd lengan atas
i: tuberositas radii, fascia antebrachii

4. M coracobrachialis

o: proc coracoideus
i: pertengahan humerus bag medial
f: antefl & add lengan atas

5. M subscapularis

o: fossa scapularis
i: tuberculum minus
f: endorot & add LA

6. M teres major

o: ang inf + m axill scap
I : crista tub minoris
f: add, endorot, dorsofl LA

7. M. triceps brachii

A. Cap longum

o: tub infraglenoidalis
f: add & dorsofl LA

B. Cap laterale

o: dorsal hum prox sulc n r

C. Cap mediale

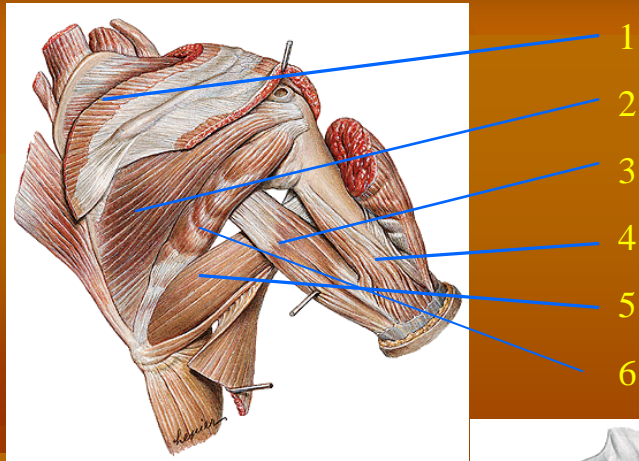
o: dorsal hum distal sul n r

i: olecranon

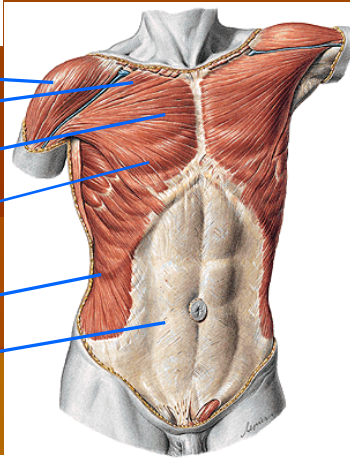
F: ekstensi LB

8. M anconeus

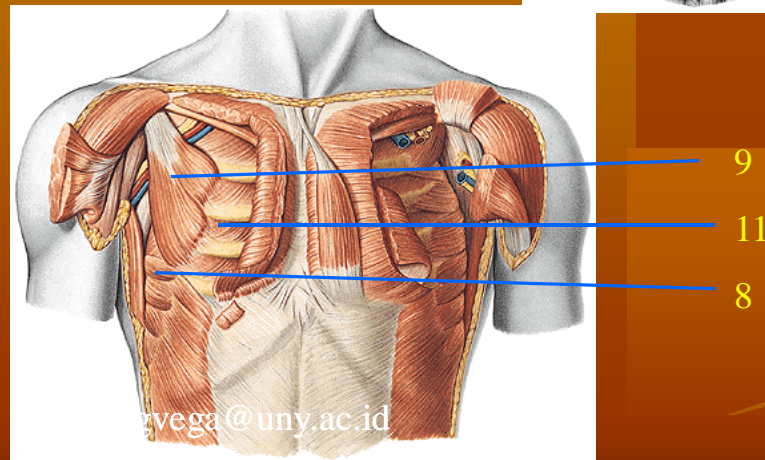
o: epicondylus lat hum
i: marg dors ulna bag prox
f: extensio LB



1
2
3
4
5
6



10
7A
7B
7C
12
13



9
11
8

vega@uny.ac.id

1. M supraspinatus

o: fossa supraspinata
i: tuberculum majus
f: abd LA

2. M infraspinatus

o: fossa infraspinata
i: tuberculum majus
f: exorot & add LA

3. M triceps br cap long

4. M triceps br cap lat

5. M teres major

6. M teres minor

o: margo axill scap
i: tuberculum majus
f: exorot & add LA

7. M pectoralis major

A. Pars clavicularis

o: 2/3 med clav
f: add, antefl, endorot LA

B. Pars sternocostalis

o: sternum+costa 1-6
f: add, endorot LA

C. Pars abdominalis

o: vag m recti abd
f: add LA

i: crista tub majoris hum

F: add, endorot LA

8. M serratus anterior

o: costa 1-9
i: ang med scap, margo
vert scap, angulus inf
scap

f: menarik margo verteb
ke muka lateral

9. M pectoralis minor

o: costa 3-5

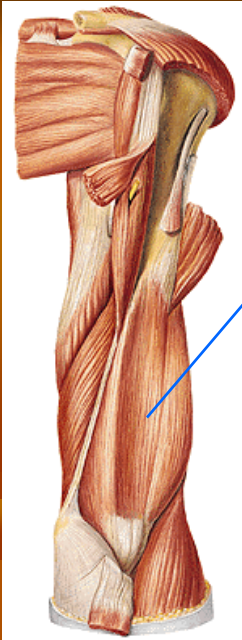
i: proc coracoideus scap
f: menarik proc
coracoideus ke muka
bwh

10. M deltoideus

11. M intercostalis

12 m. obliquus ext abd

13. M rectus abdominis



1

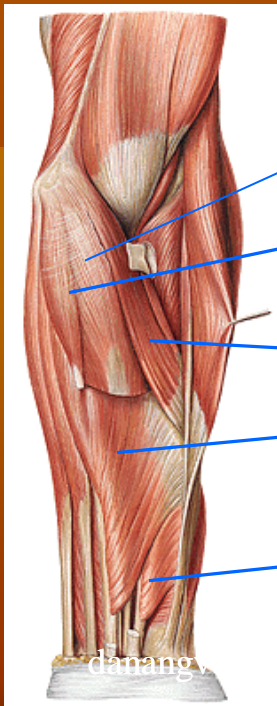
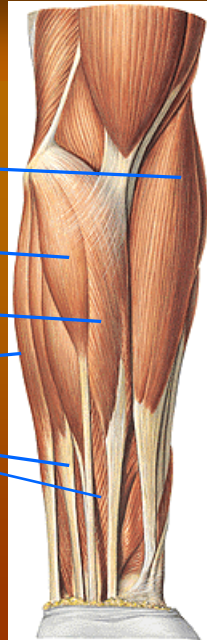
2

4

3

5

6



3

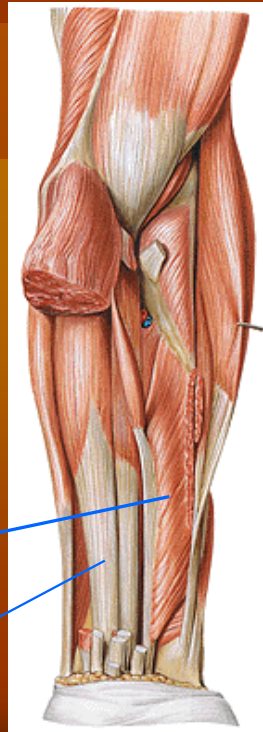4

7

6

8

9



danang...@uny.ac.id

1. M brachialis

o: pertengahan bwh dataran ventral hum

i: tuberositas ulnae

f: fleksi LB

2. M brachioradialis

o: margo lat hum prox epic lat hum

i: proc stiloideus radii

f: fleksi, supinasi LB

3. M fleksor carpi radialis

o: epic med hum, proc coronoideus

I : basis ossis metacarpalis II & III

f: fleks & pron LB, fleks & abd rad tangan

4. M palmaris longus

o: epic med hum, proc coronoideus ulnae

i: aponeurosis palmaris

f: fleks, pron LB, flek tgn

5. M fleksor carpi ulnaris

o: capit hum, epic med hum, cap & margo dorsale ulnae

i: os pisiforme

f: fleks, abd ulnar tgn

6. M fleksor digitorum sup

o: cap hum uln: epic med hum, proc coronoideus ; cap rad: dat ventral rad

i: sisi2 phalanx media

f: fleksLB, fleks phalanx, fleks tgn, abd ulnar tgn

7. M pronator teres

o: cap hum: epic med hum cap ulnare: proc coron

i: pertngn ventral rad

f: fleks, pronasi LB

8. M fleksor pollicis longus

o: dataran ventral rad

i: phalanx dist jari I

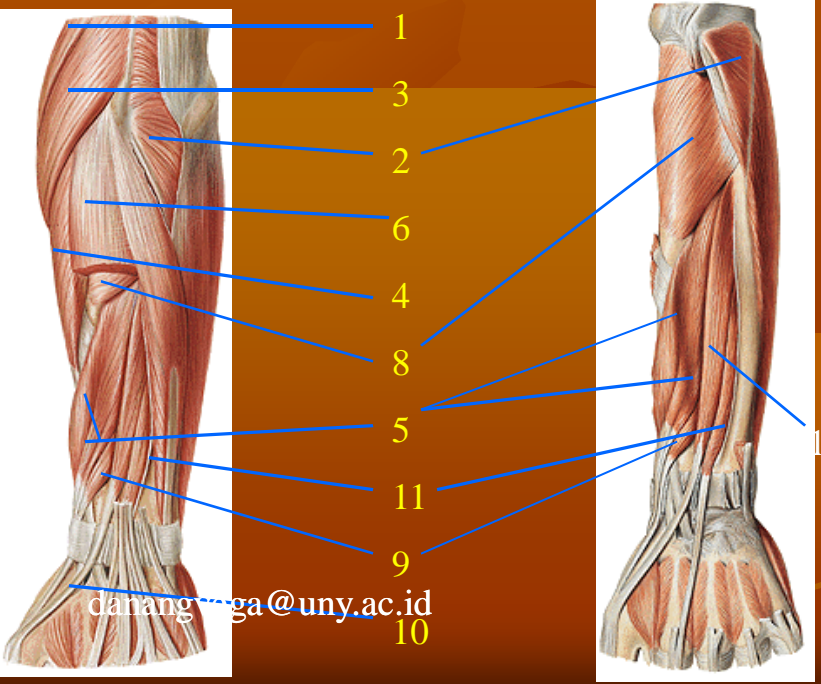
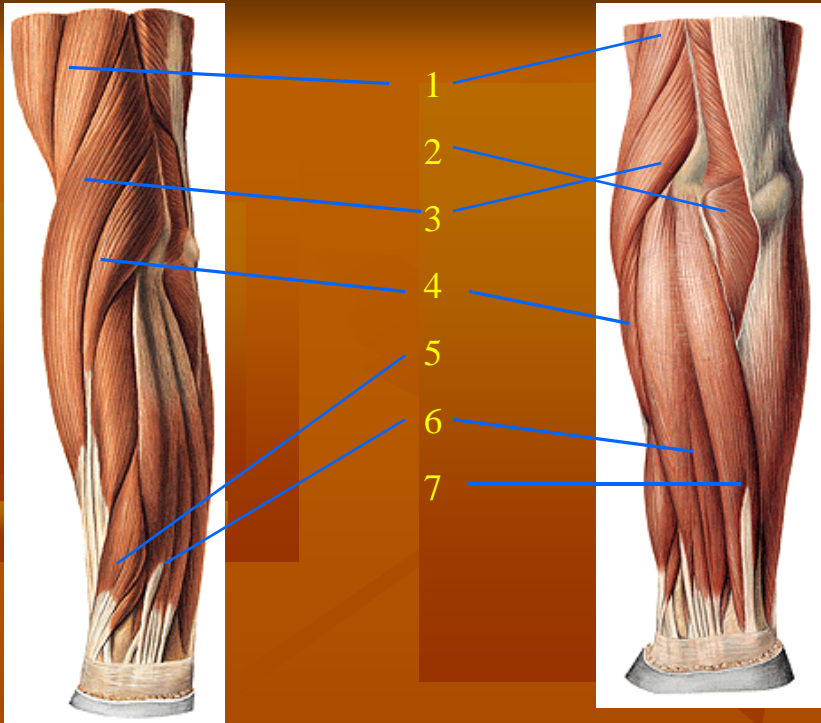
f: fleks phal, opposisi jr I, flek tgn, abd rad tgn

9. M fleksor digitorum profundus

o: dat ventral ulnae

i: phalanx dist jari II-V

f: fleks phal, fleks tgn, abd ulnar tgn



1. M brachioradialis

2. M anconeus

3. M extensor carpi rad long

o: marg lat hum, prox epic lat humeri

i: basis ossis metacarp II
f: ext & sup LB, ext tgn, abd rad tgn

4. M ext carp rad brevis

o: epic lat humeri

i: basis ossis metacarp III
f: ext & supin LB, ext tgn, abd rad tgn

5. M abd pollicis longus

o: dat dorsal ulnae & radius, membr interossea

i: basis ossis metacarp I
f: sup LB, abd jr I abd rad tgn

6. M extensor digitorum

o: epic lat humeri

i: phalanx med & distalis ji II-V
f: ext LB, ext tgn, ext phalanx

7. M extensor carp ulnaris

o: cap hum: epic lat hum, cap ulnare: margo dors ulnae

i: basis ossis metacarp V
f: ext LB, ext tgn, abd ulnar tgn

8. M supinator

o: epic lat hum, crista m supinatoris ulnae

i: dataran ventr rad sebelah distal tuberositas radii
f: supinasi LB

9. M ext pollicis brevis

o: margo dors uln, dat dors rad, membr interossea

i: basis phlx prox jr I
f: ext phlx prox jr I, ext tgn, abd rad tgn sup LB

10. M ext pollicis longus

o: margo dors ulnae

i: basis phlx dist jr I
f: ext phalx, ext tgn, abd rad tgn, supinasi LB

11. M extensor indicis

